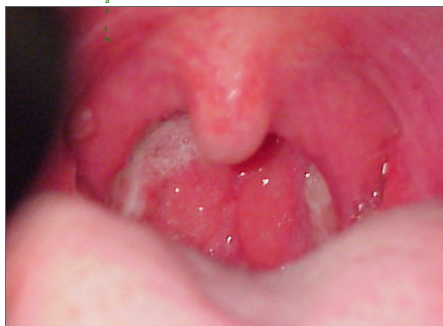

Baktériumok és gombák által okozott szájüregi infekciók /összefoglalás /

Dr Csukás Zsuzsanna

Tonsillitis acuta

- Kórokozó: Streptococcus pyogenes

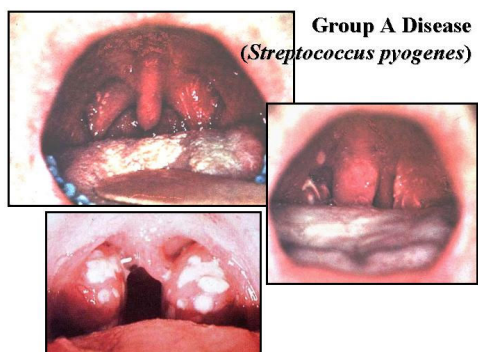


Tonsillitis (Mandelentzündung)

www.Medizin.ch

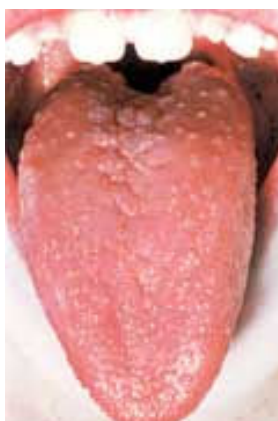Pharyngitis acuta

- Kórokozó: *S. pyogenes*



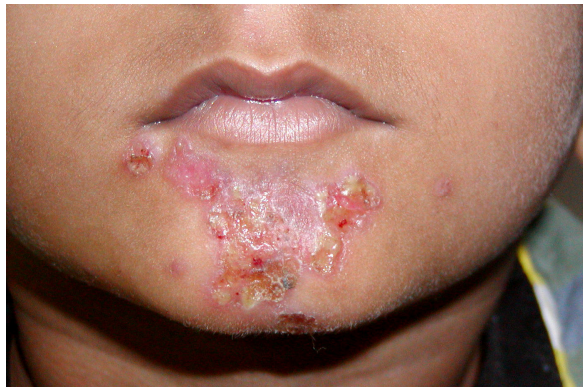Scarlat: stomatitis scarlatina

- Kórokozó: *S. pyogenes*



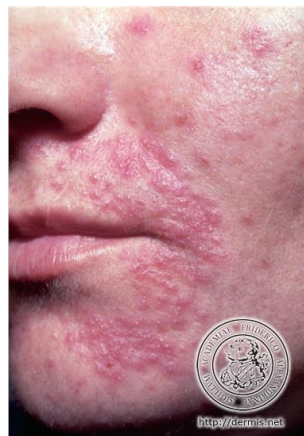
Impetigo Erysipelas

- Kórokozó: S.pyogenes



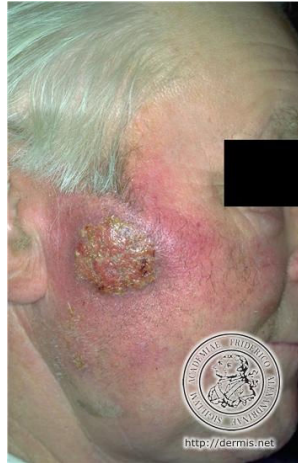Perioralis dermatitis

- Kórokozó: S. aureus



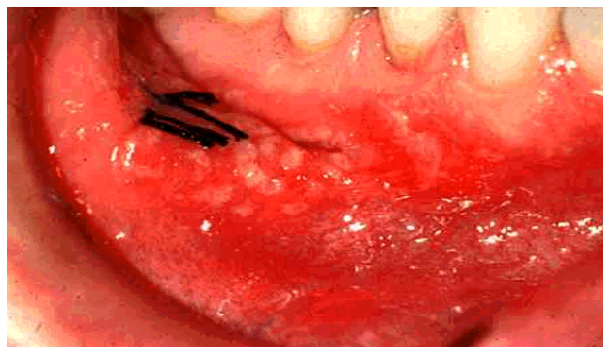
Furunculus, carbunculus

- Kórokozó: *S. aureus*



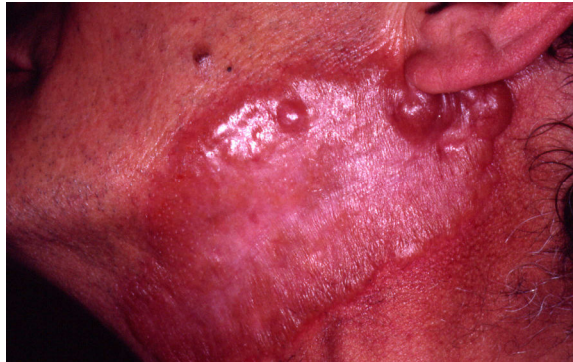Pyostomatitis vegetans

- Kórokozó: ?



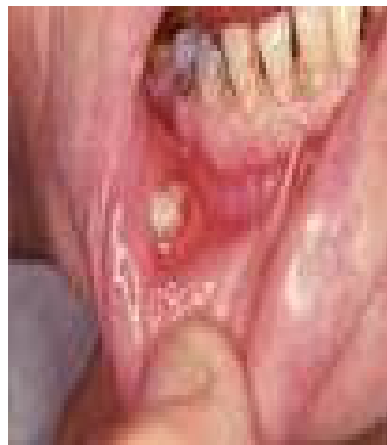TBC ---scrophulosis

- Kórokozó: M. tuberculosis

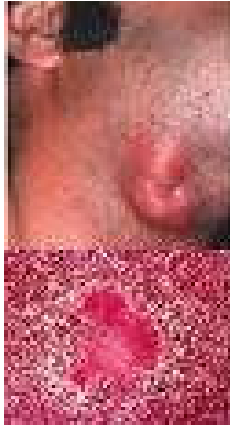


Actinomycosis – cervicofaciális lézió

- Kórokozó: A. israelii

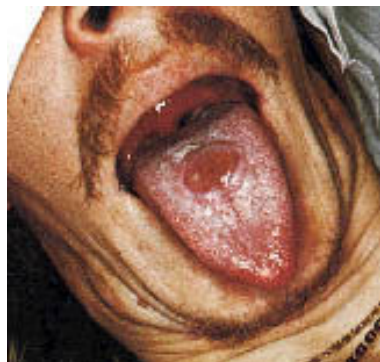

Actinomycrosis

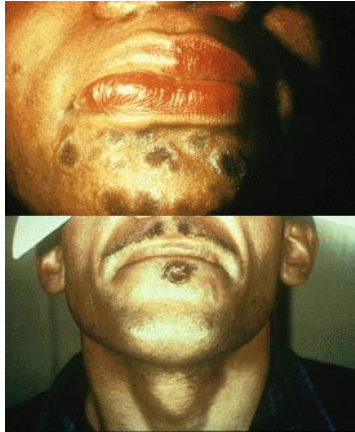

Syphilis –ulcus durum

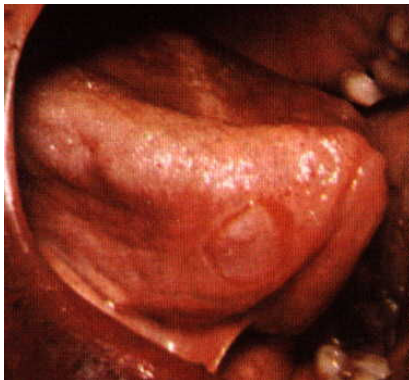
- Kórokozó: T.pallidum



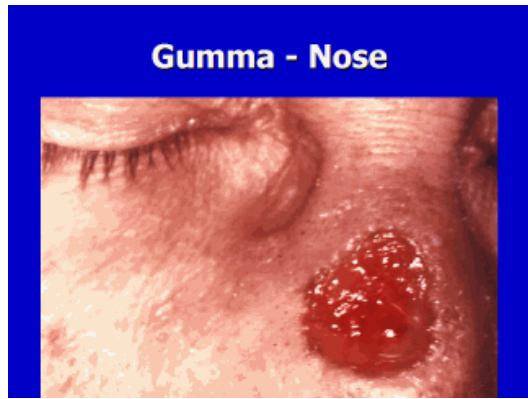
Syphilis -- exanthema



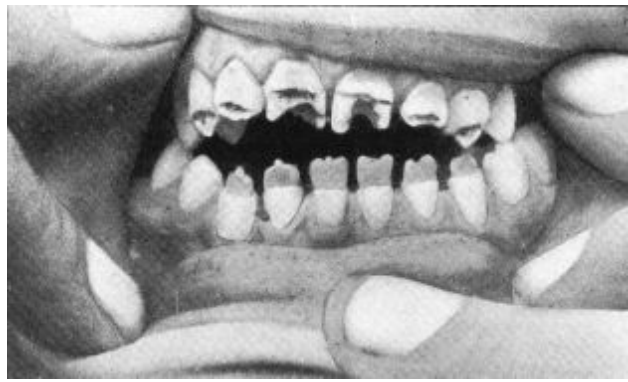
Syphilis -- enanthema



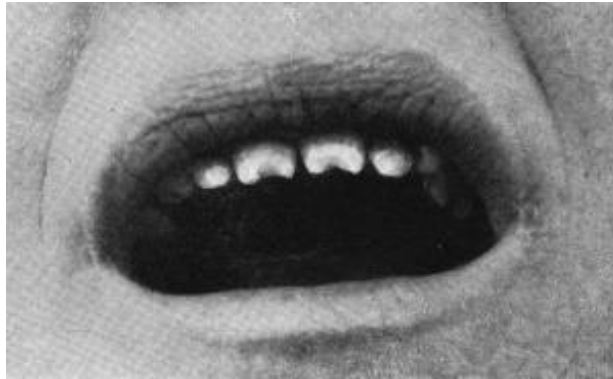Syphilis -- gumma



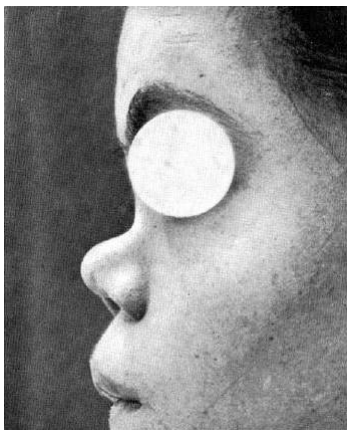
Syphilis -- connatális



 Syphilis -- connatális



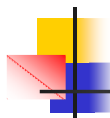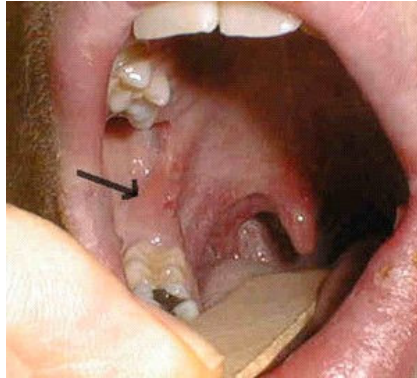
 Syphilis -- connatális



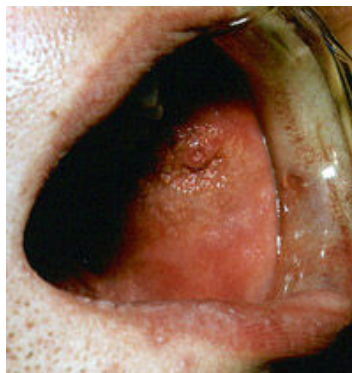

Gonorrhoea –oralis lézió

- Kórokozó: N. gonorrhoea

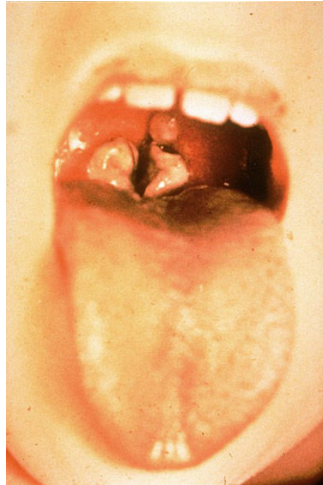

Gonorrhoea – oralis lézió



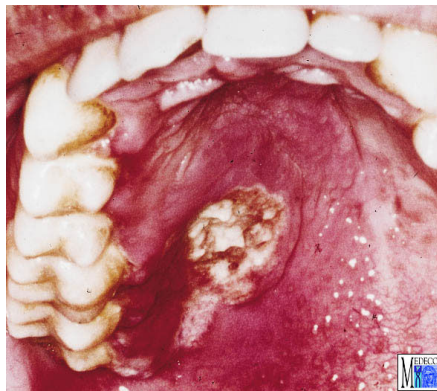
Diphtheria

- Kórokozó: *C. diphtheriae*

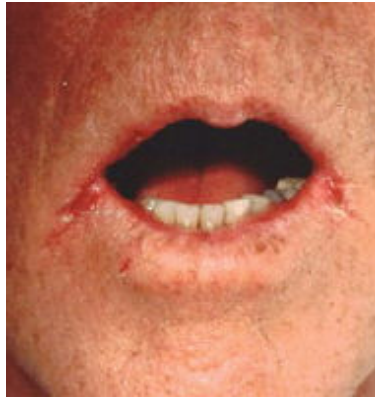

Stomatitis ulcerosa

- Kórokozók: *F. fusiforme* + *T. vincenti*



Candidiasis



Candidiasis

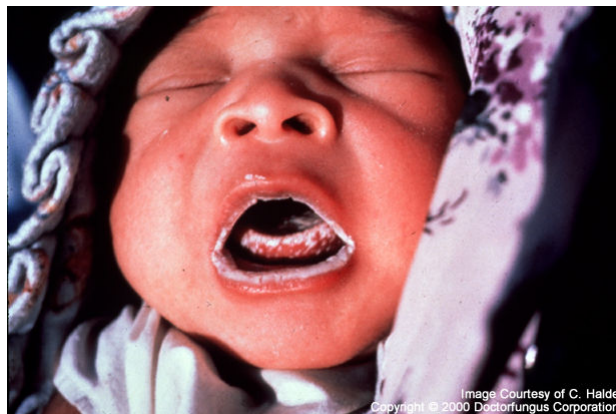
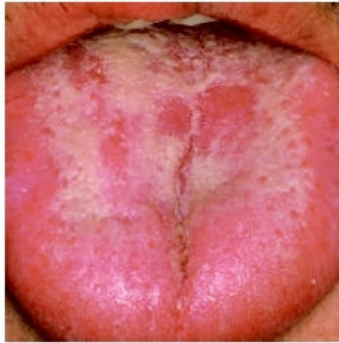
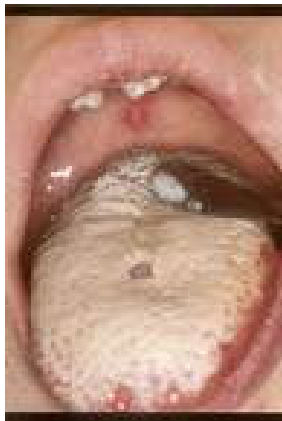Image Courtesy of C. Halde
Copyright © 2000 Doctorfungus Corporation

Candida -- soor

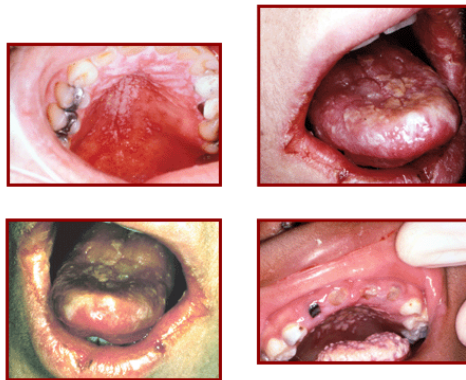


Candidiasis – pseudomembran

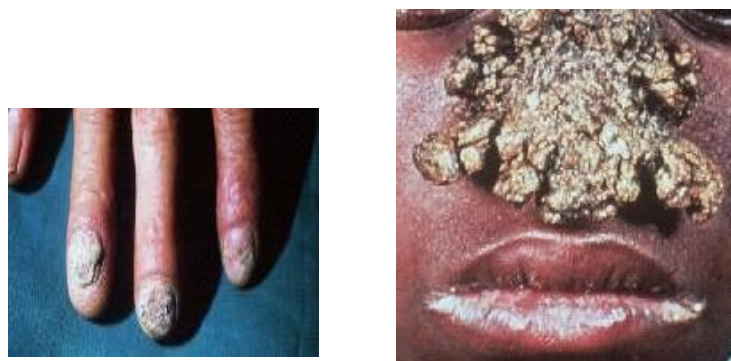- Kórokozó: *Candida albicans*



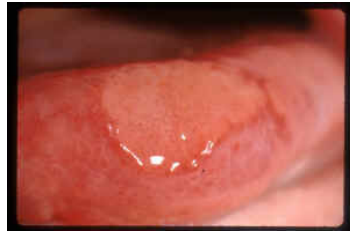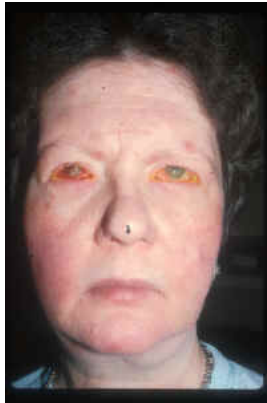
Candidiasis – atrophía, erythema



Candidiasis – krónikus hiperplázia

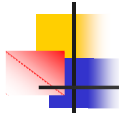


Candidiasis – krónikus mucocutan folyamat



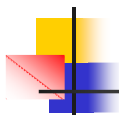
Szájüregi infekciók kórokozói

- Normál oralis baktérium flóra:
 - ** Streptococcus mitis, S. mutans, S.anginosus...
 - ** Neisseria pharyngitidis
 - ** Apathogén corynebacterium
 - ** Actinomyces naeslundii, A.viscosus
 - ** Veillonella sp.
 - ** Anaerob spóra nélküli G+ és G- coccusok és pálcák



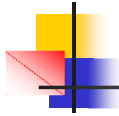
Krónikus marginális gingivitis

- Streptococcus sanguis, S. milleri
- Actinomyces israelii, A. naeslundii
- Prevotella intermedia
- Capnocytophaga sp.
- Fusobacterium nucleatum
- Veillonella sp.



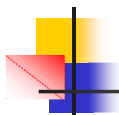
Krónikus periodontitis

- Porphyromonas gingivalis
- Prevotella intermedia
- Fusobacterium nucleatum
- Bacteroides sp.
- Actinobacillus actinomycetemcomitans
- Eubacterium sp.
- Capnocytophaga sp.
- Spirocheták



Agresszív periodontitis

- Actinobacillus actinomycetemcomitans
- Capnocytophaga sp.
- Porphyromonas gingivalis
- Prevotella intermedia



Cariogén baktériumok

- Streptococcus mutans
- Lactobacillus acidophilus
- Veillonella sp.
- Actinomyces odontolyticus
- Eubacterium saccharolyticum
- Propionibacterium sp.