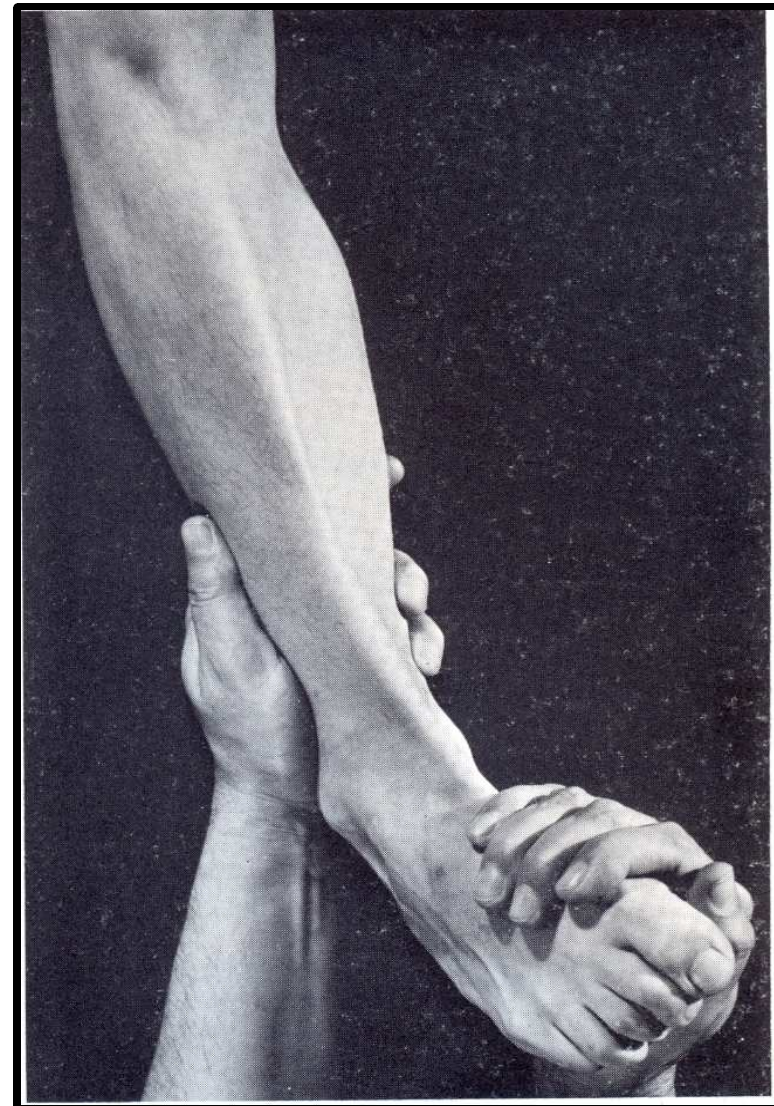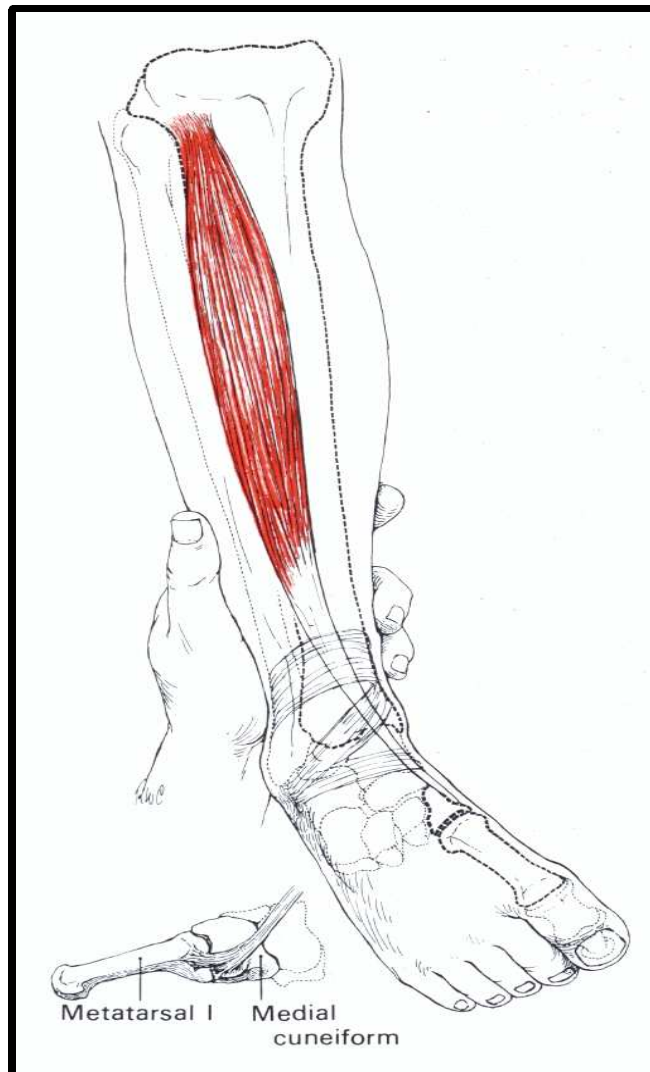


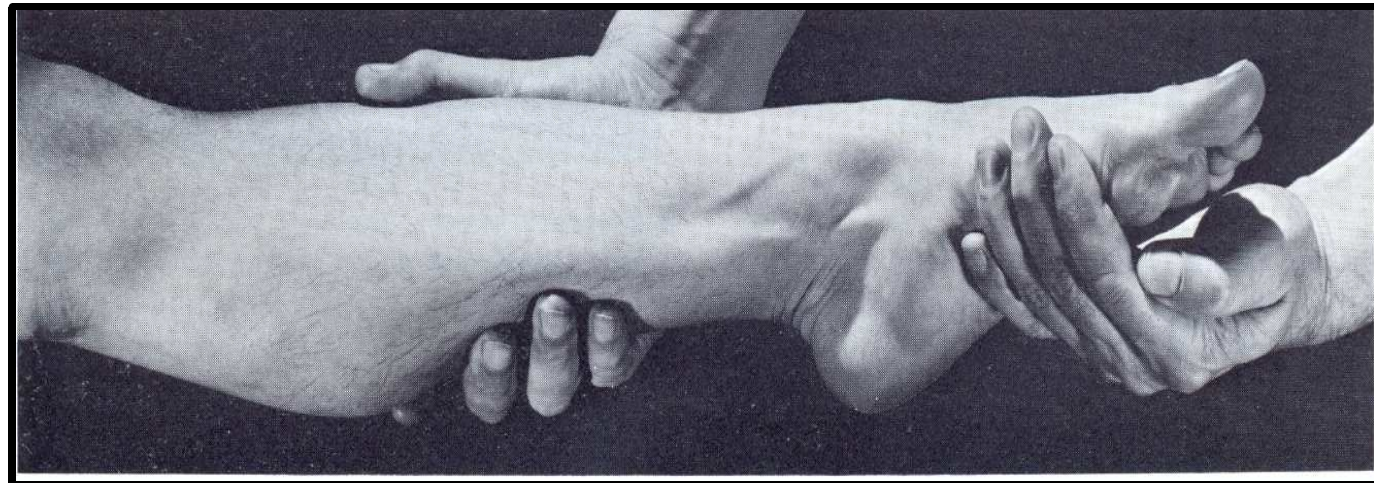
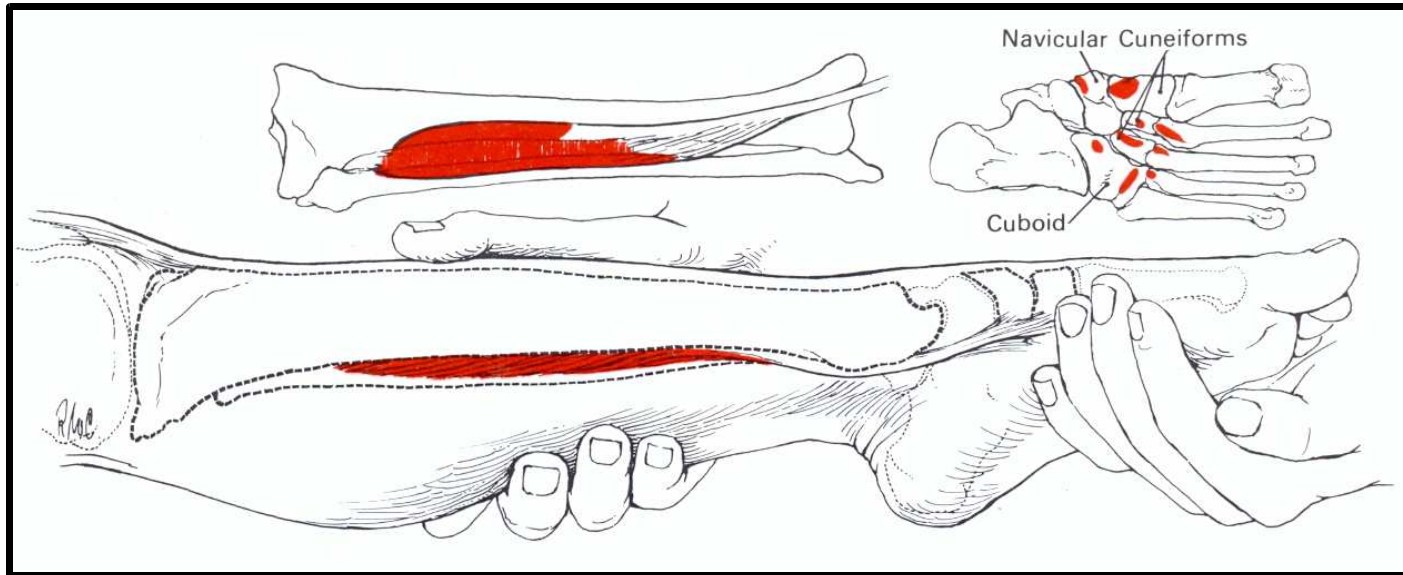
Láb izomvizsgálat

Balogh Ildikó főisk.docens

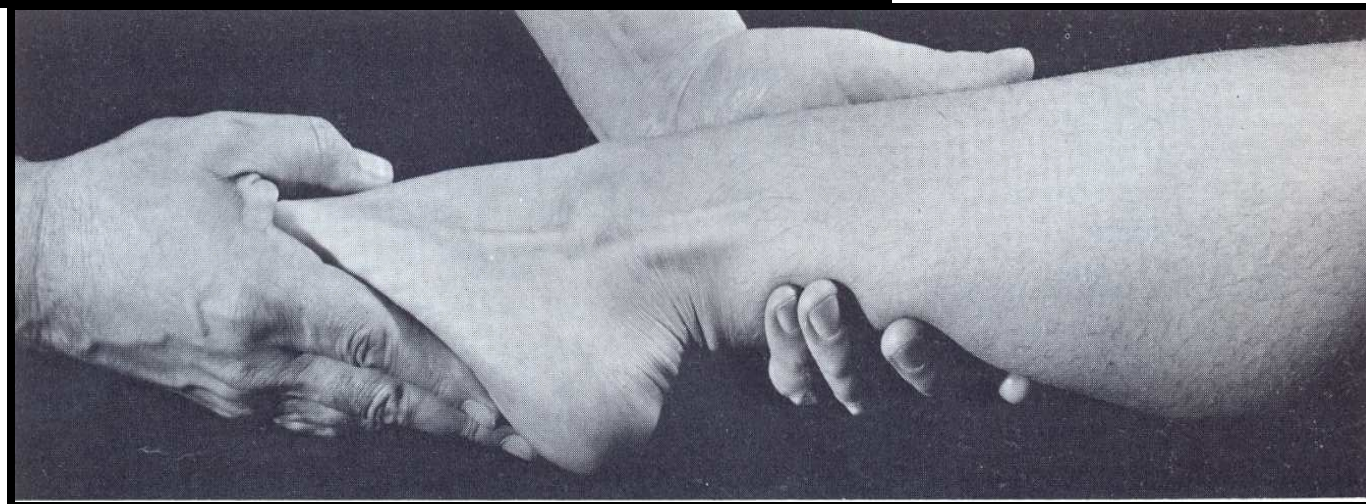
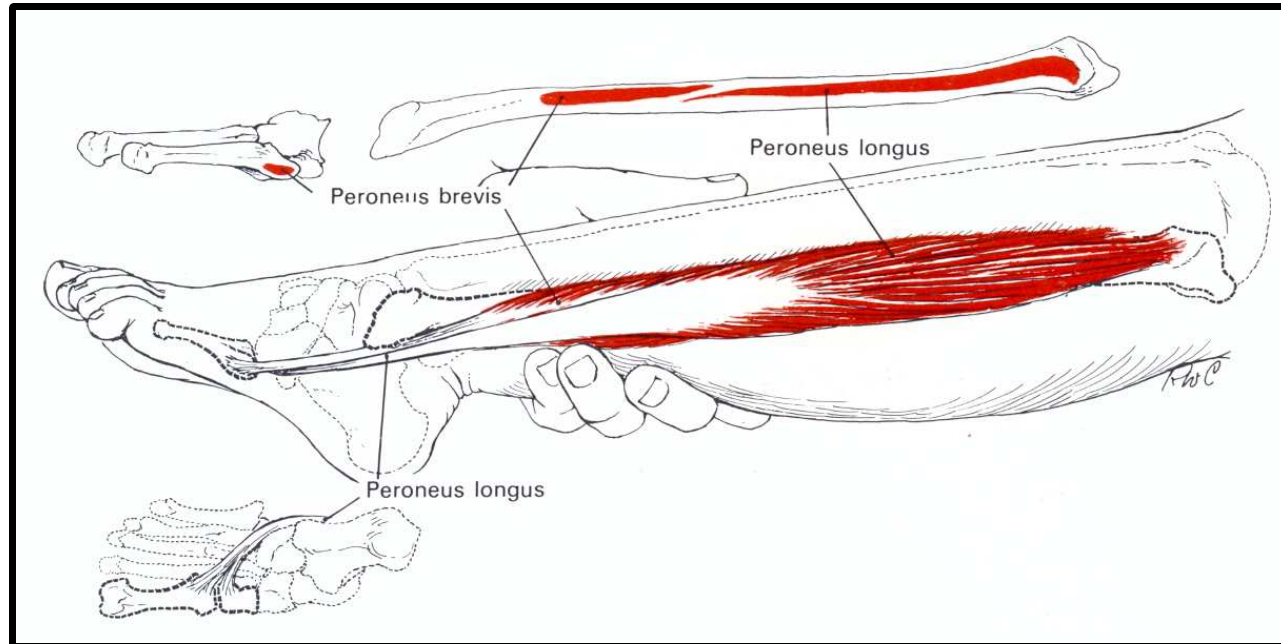
m.tibialis anterior



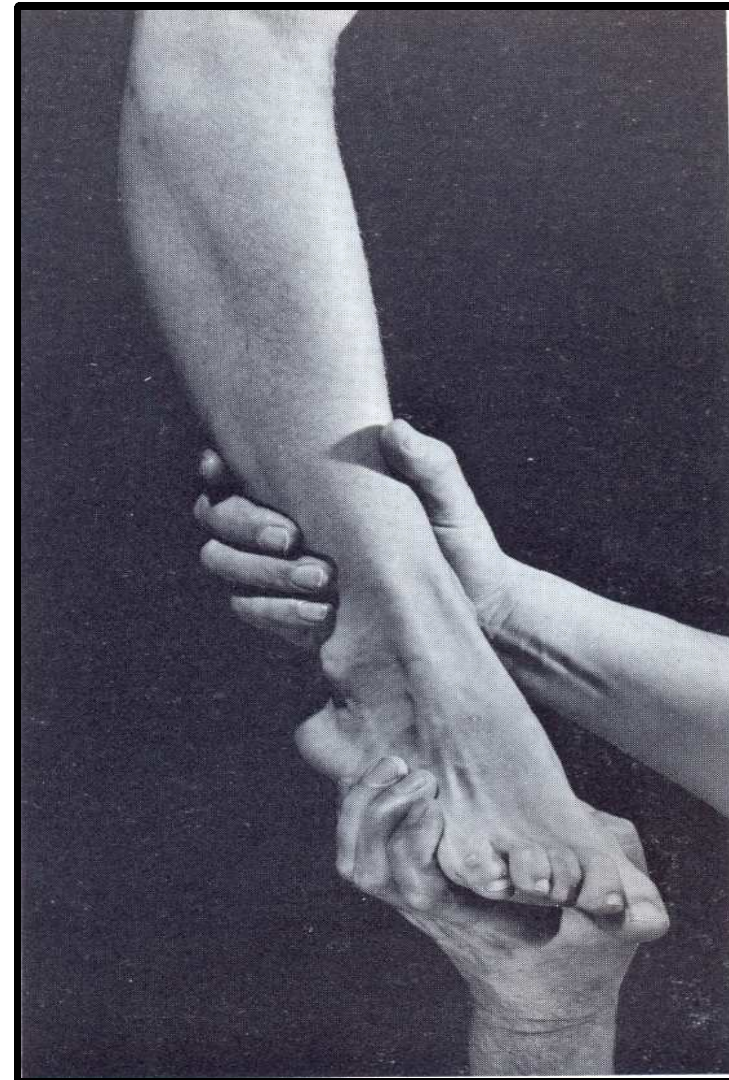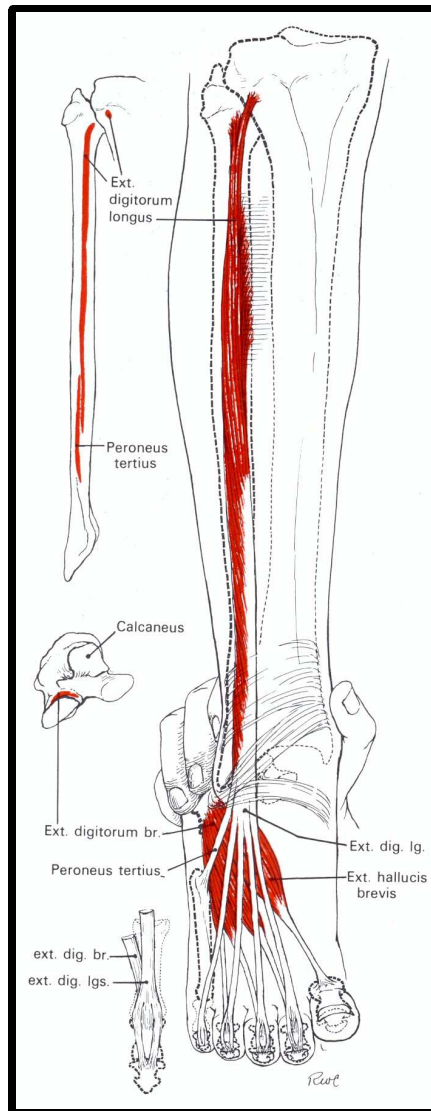
m.tibialis posterior



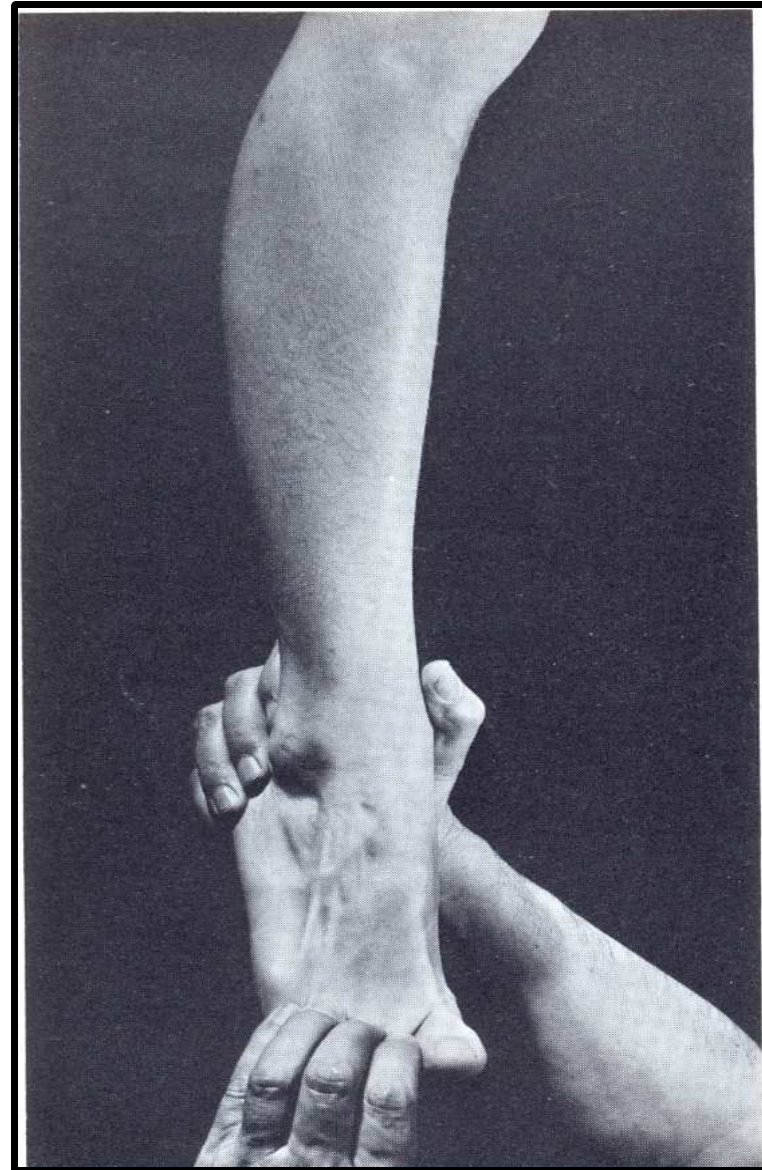
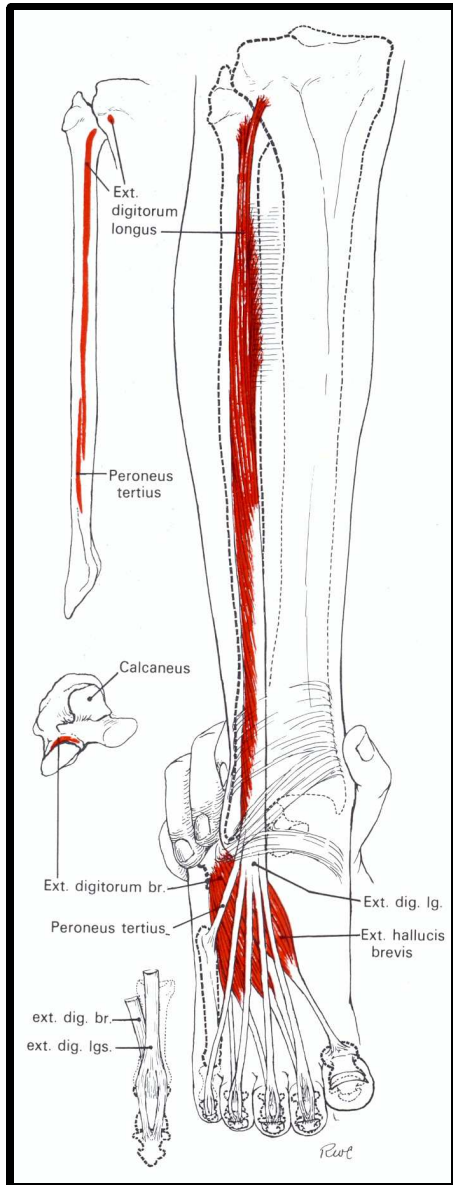
m.peroneus longus, m.peroneus brevis



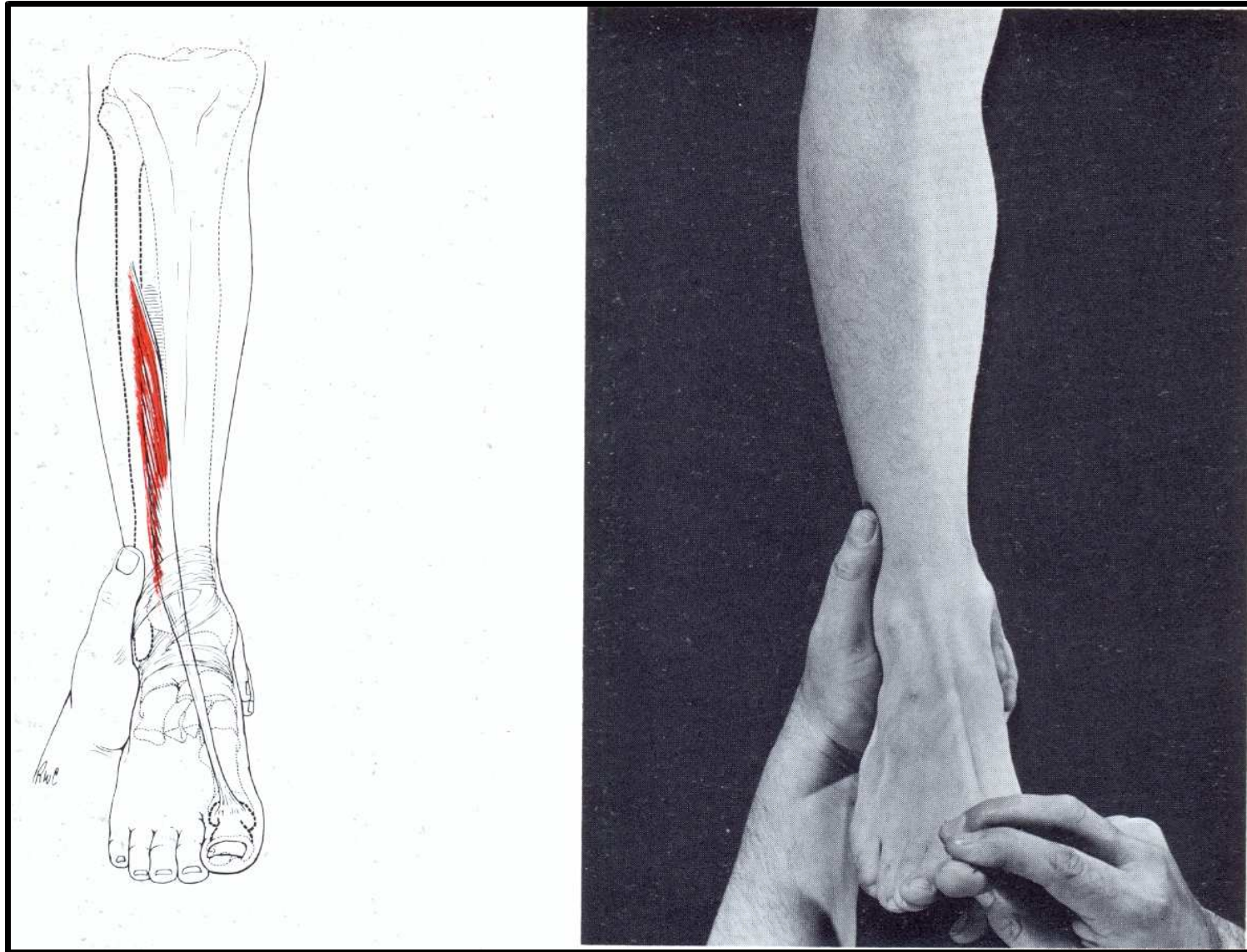
m.peroneus tertius



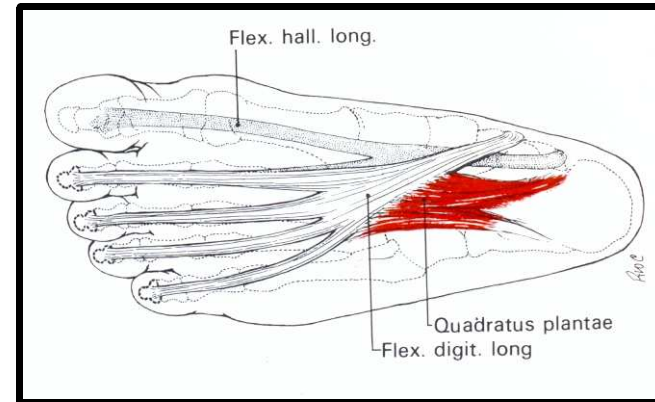
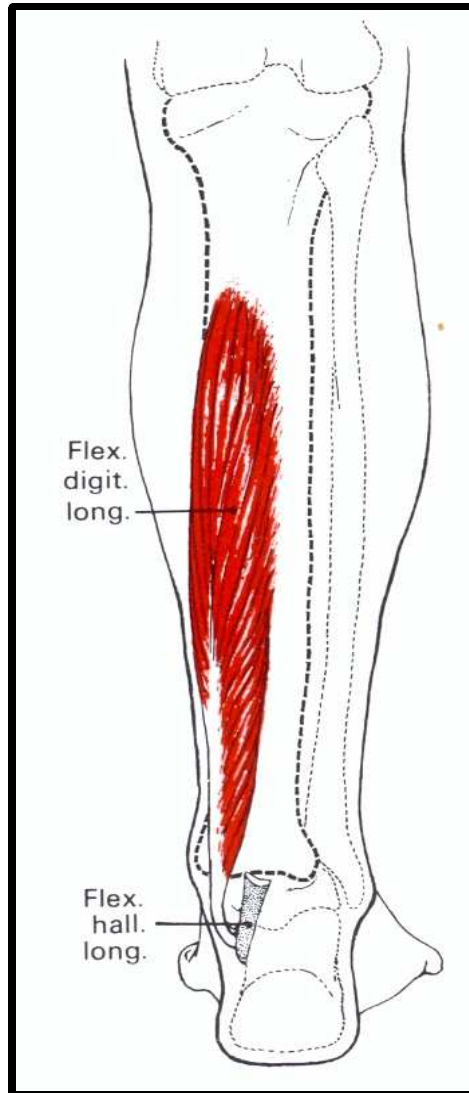
m.extensor digitorum longus, m.extensor digitorum brevis, m.extensor hallucis brevis



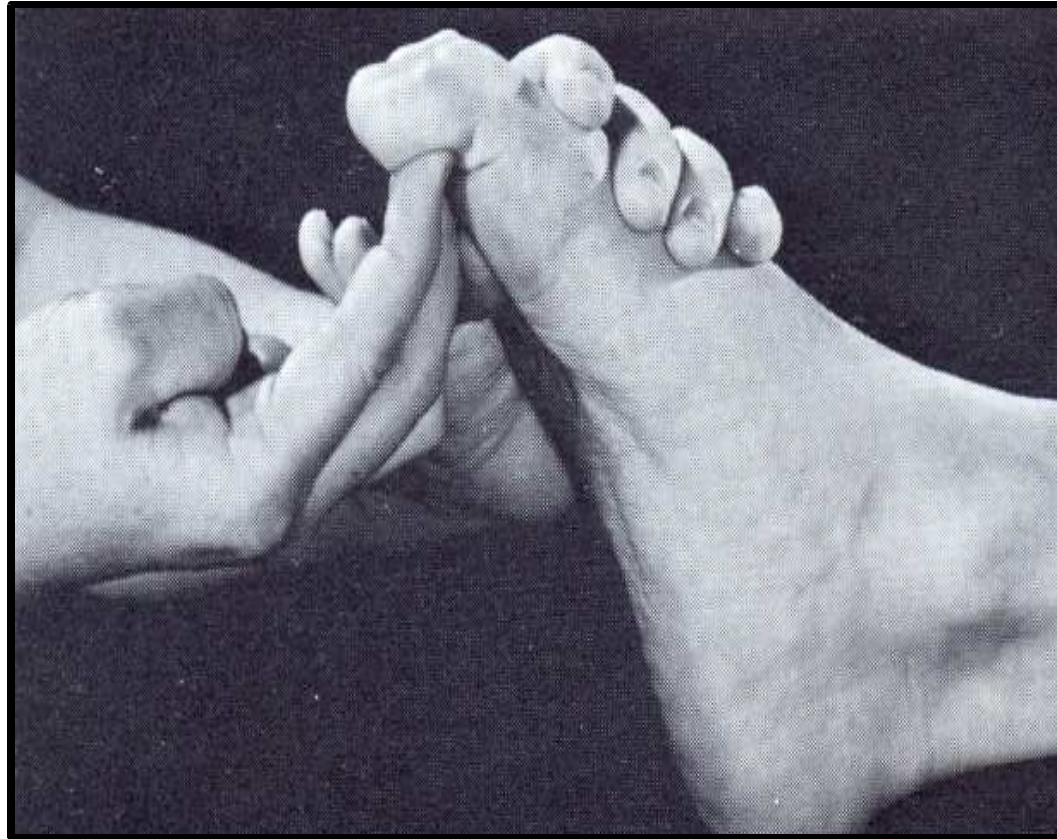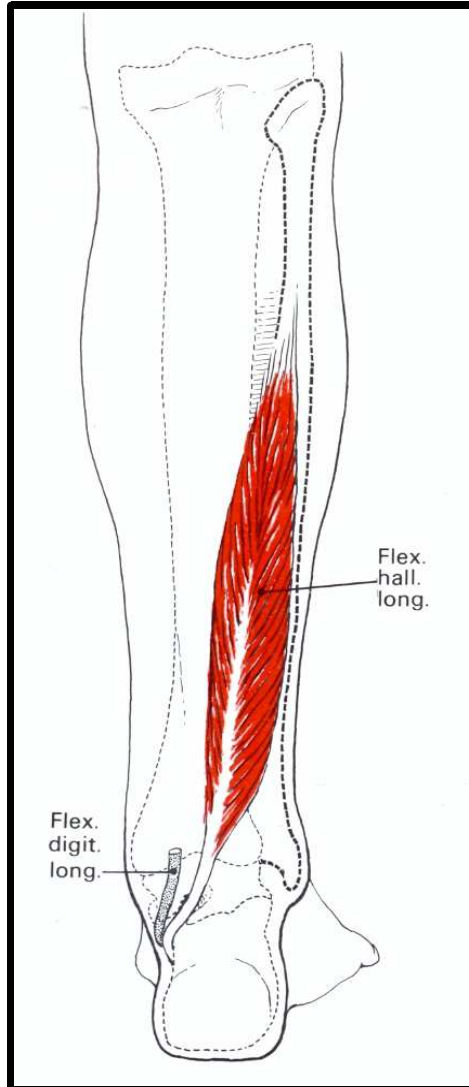
m.extensor hallucis longus



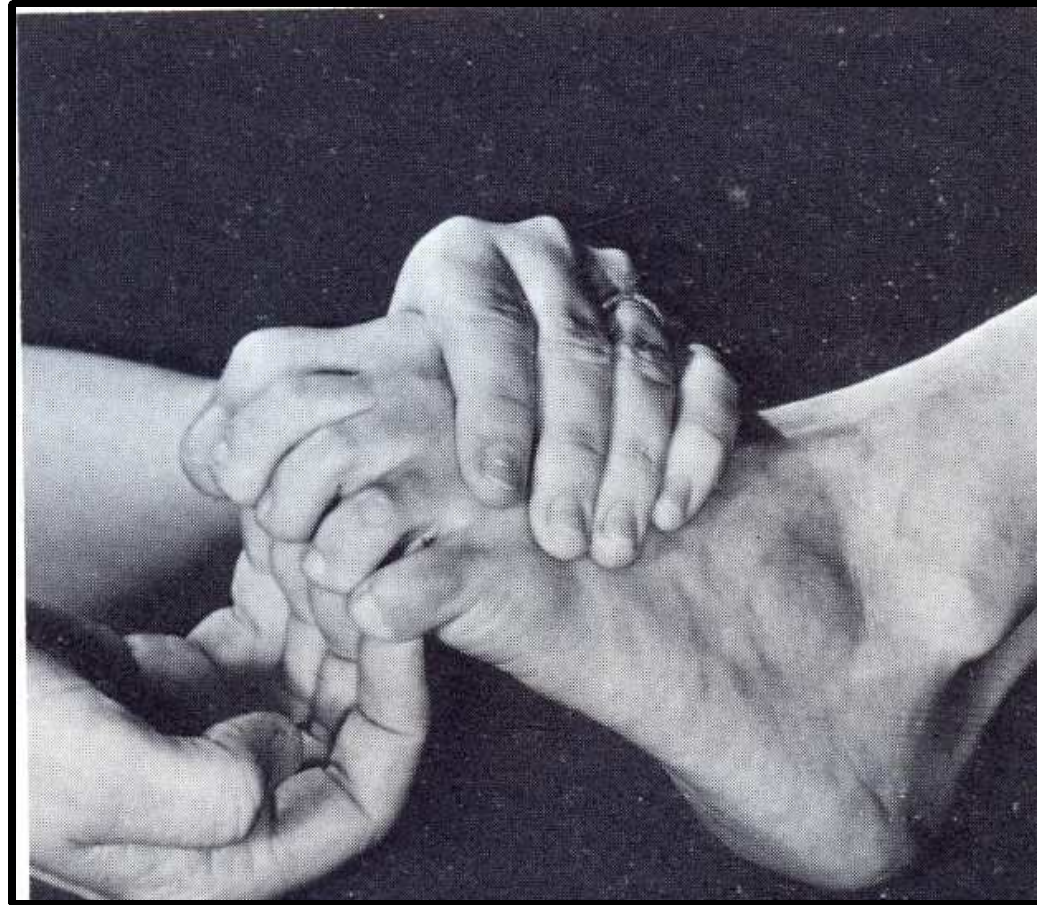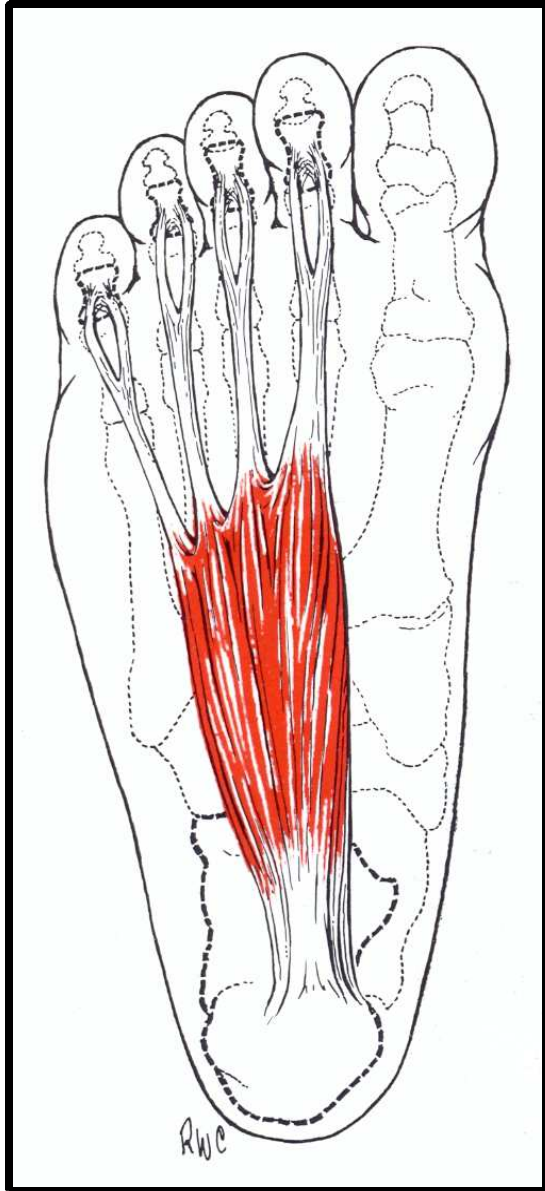
m.flexor digitorum longus, m.quadratus plantae



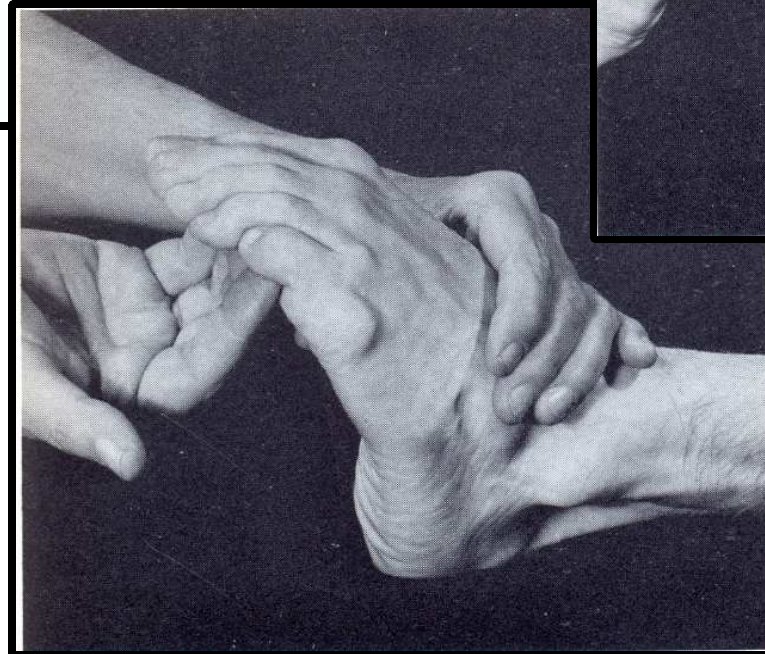
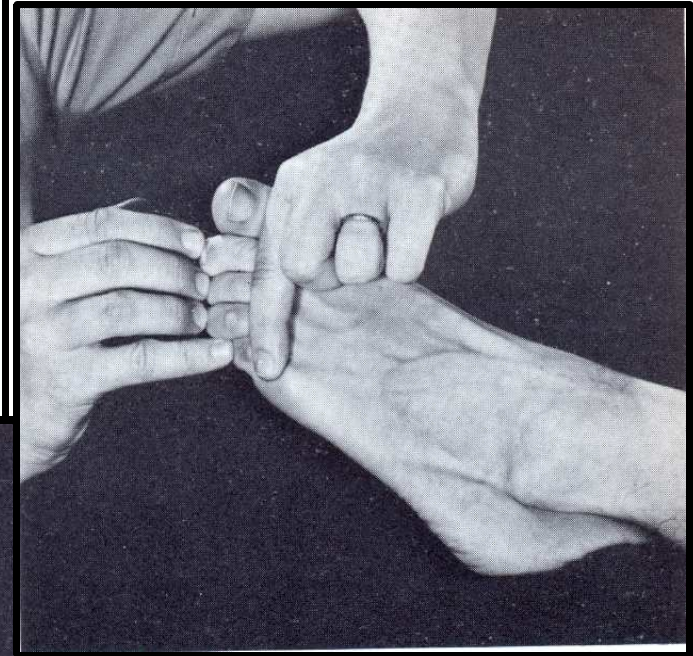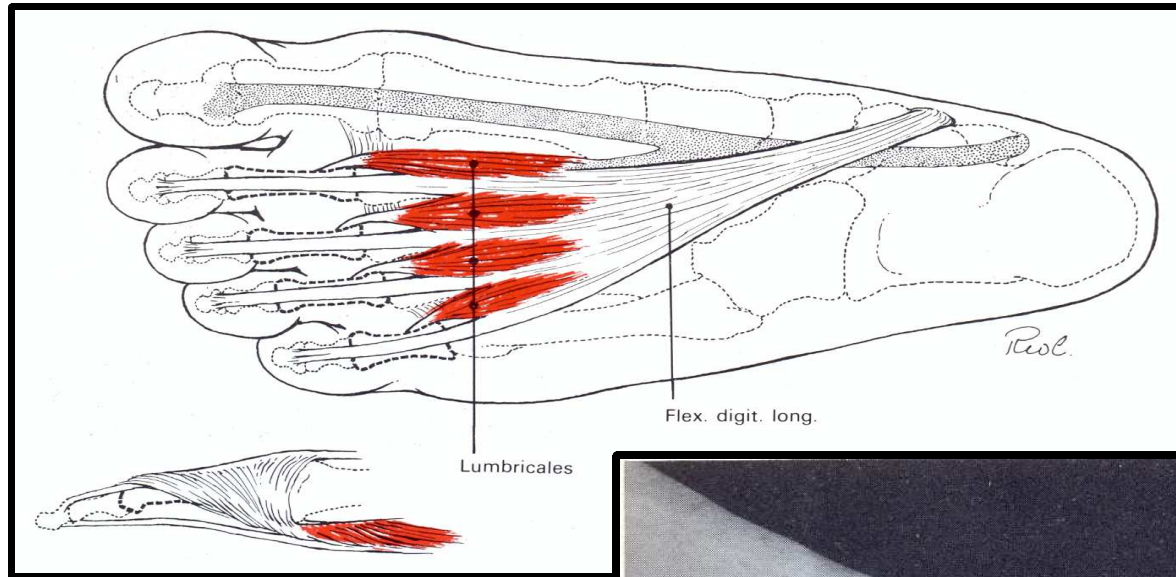
m.flexor hallucis longus



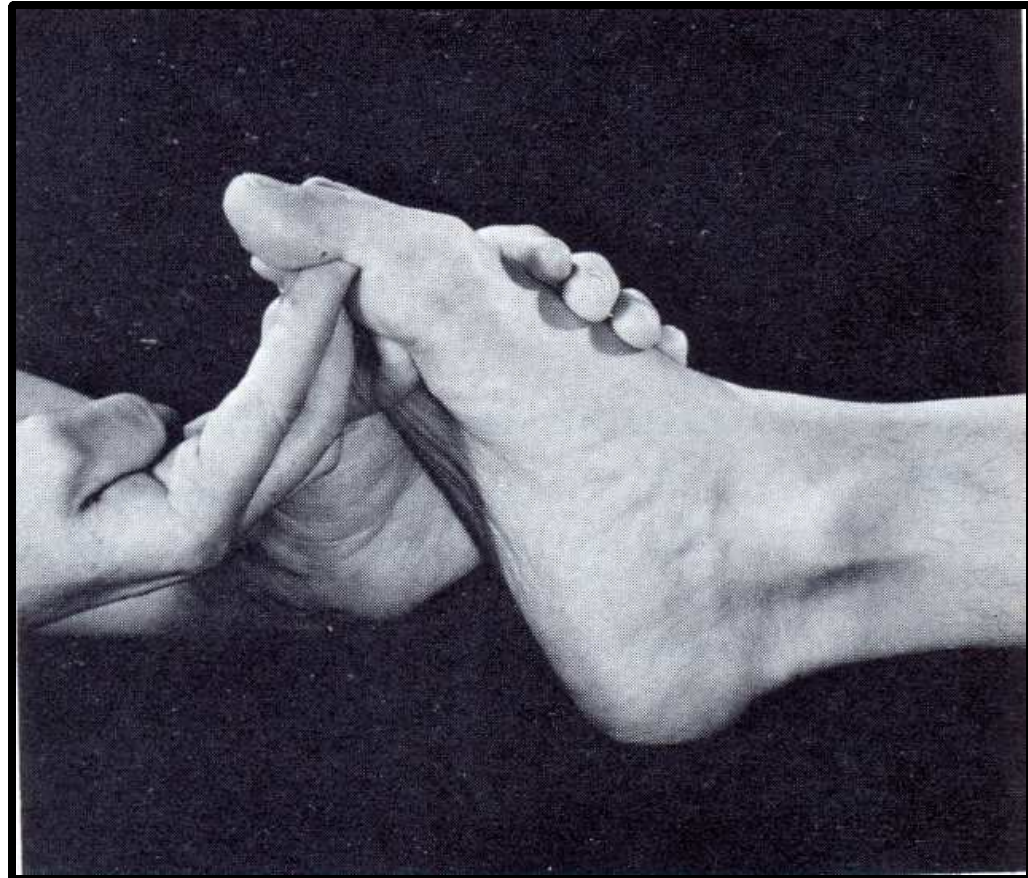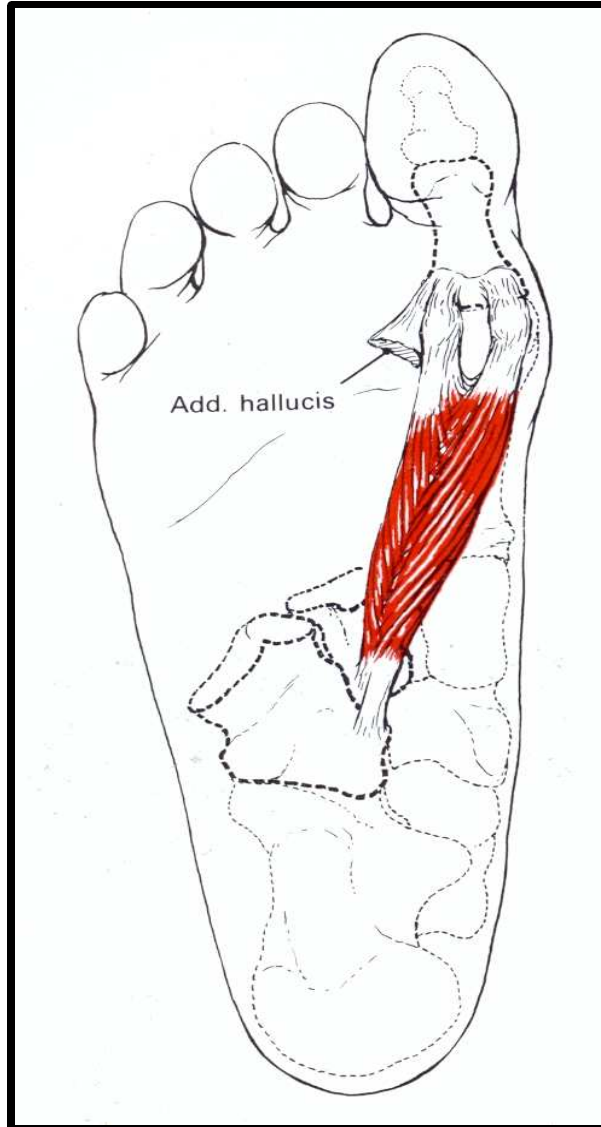
m.flexor digitorum brevis



mm.interossei, mm.lumbricales



m.flexor hallucis brevis



m.abductor hallucis

